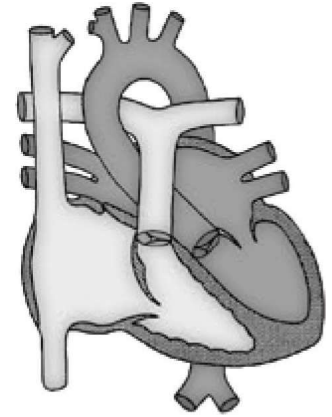
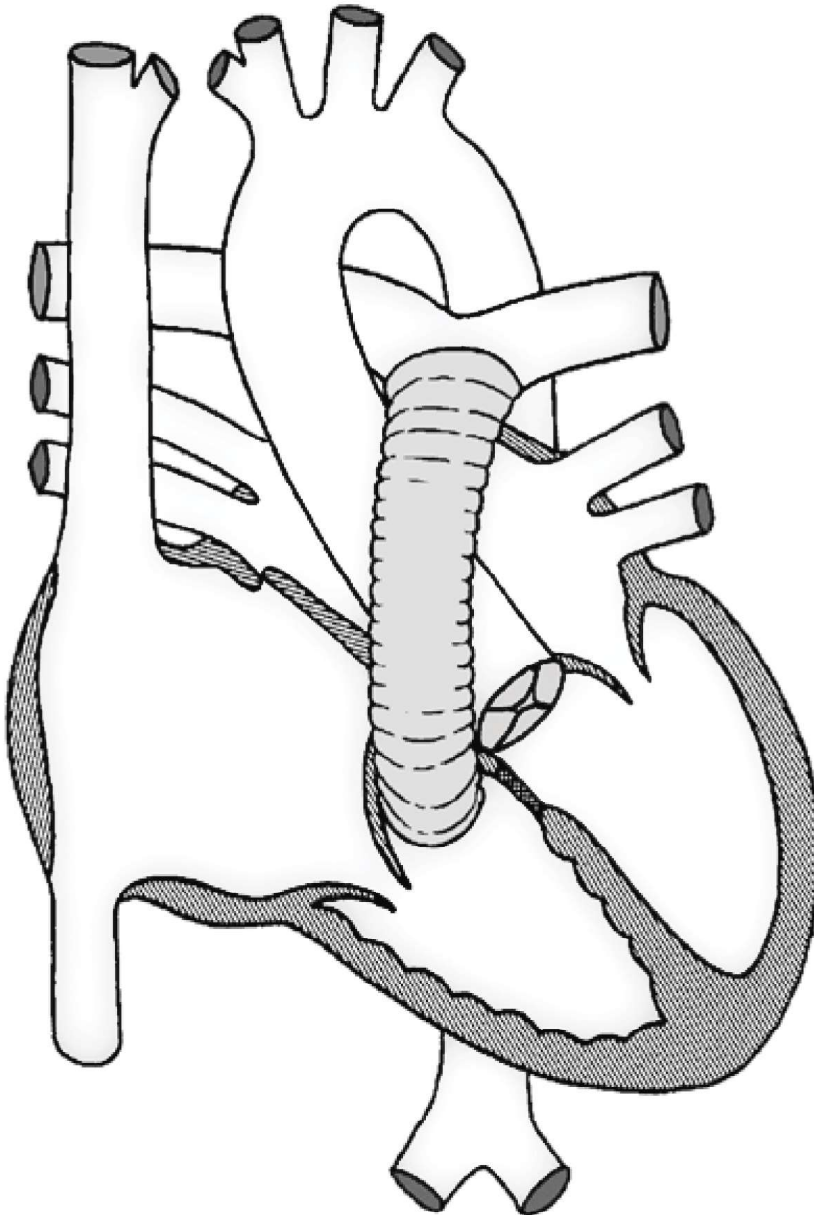




CONDUIT VENTRICULE DROIT - ARTÈRE PULMONAIRE



Cœur normal